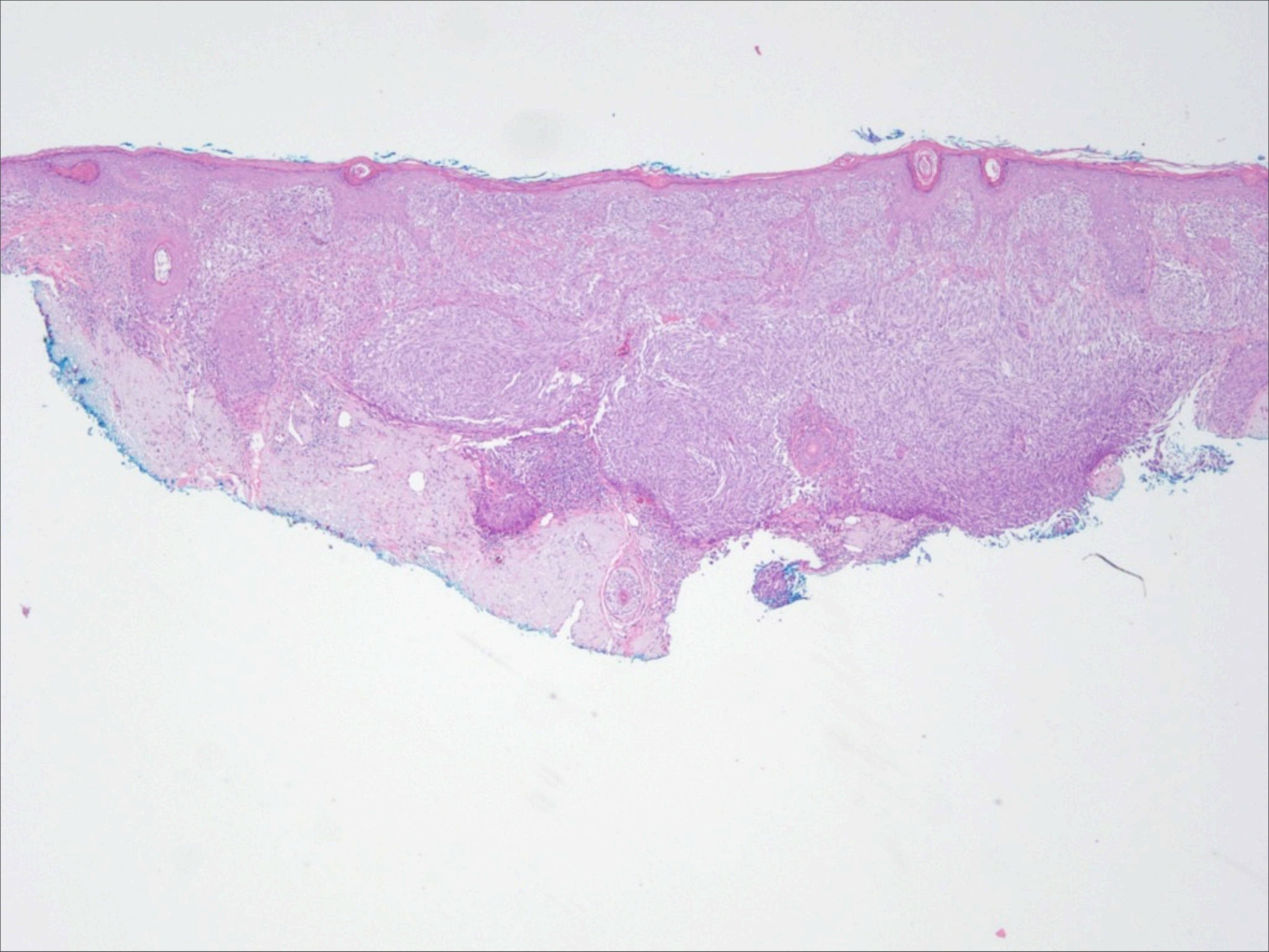


# Dermatopathology

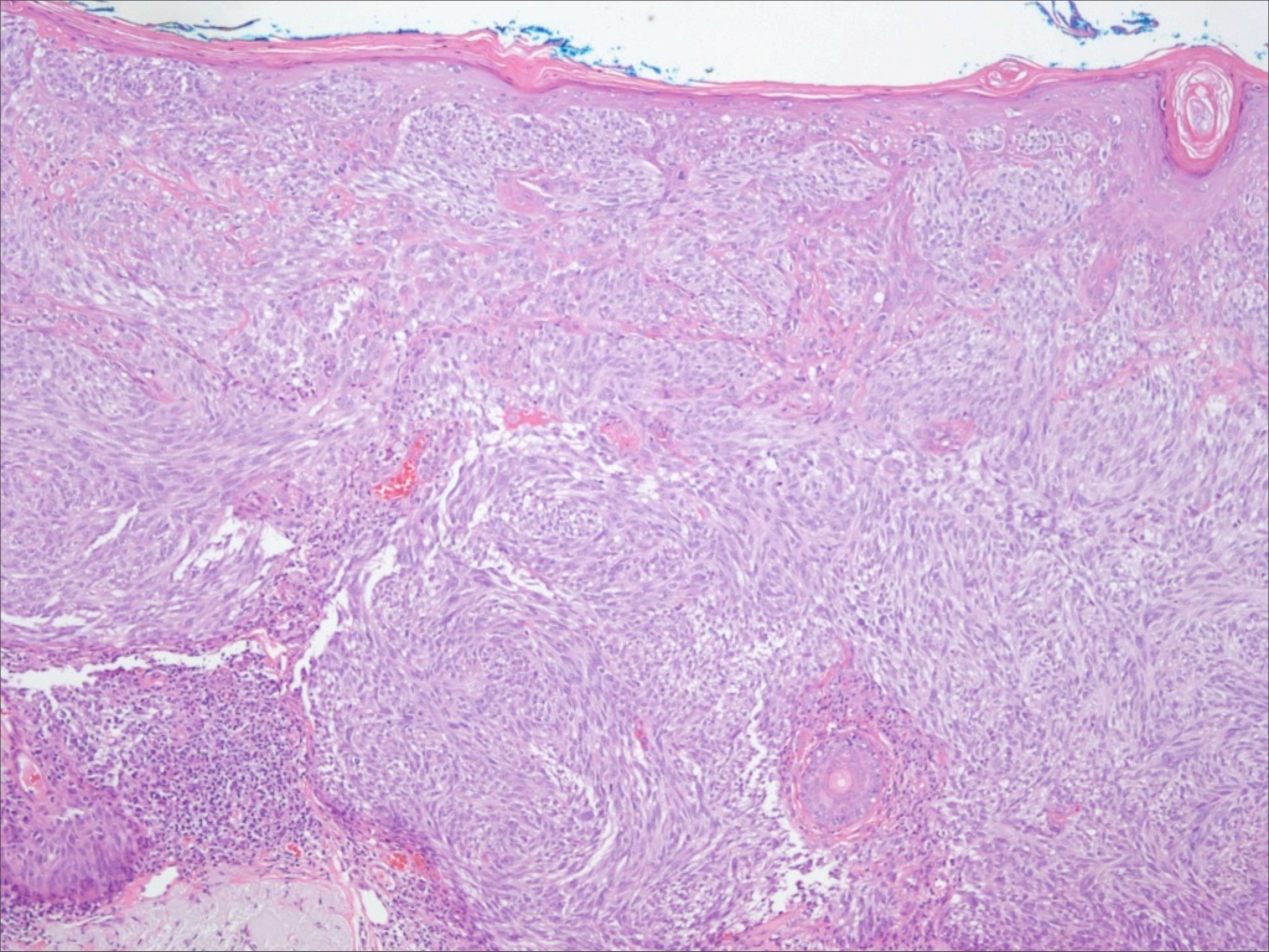
## Slide Review Part 145

Paul K. Shitabata, M.D.  
Dermatopathology Institute  
Torrance, CA

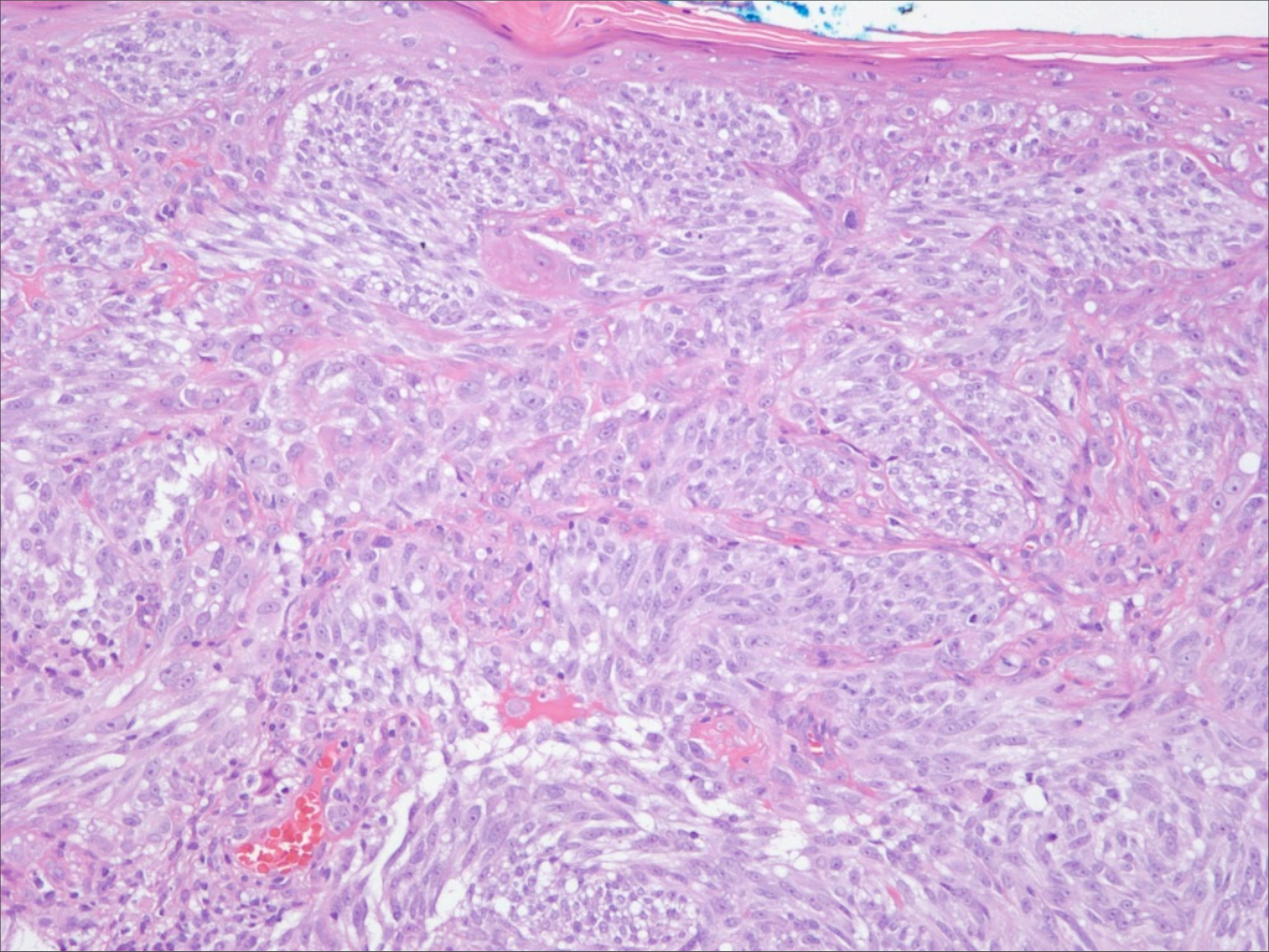




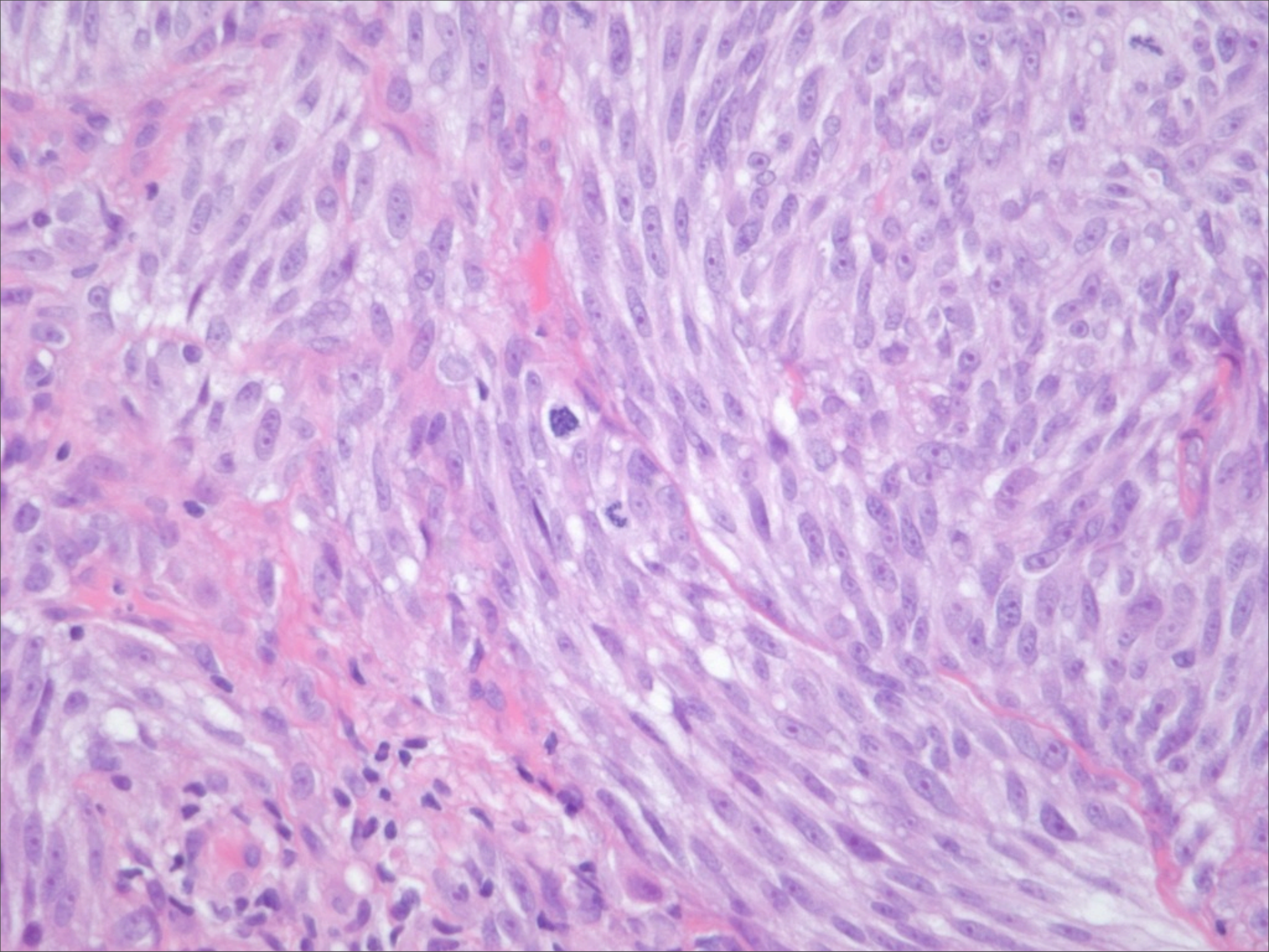




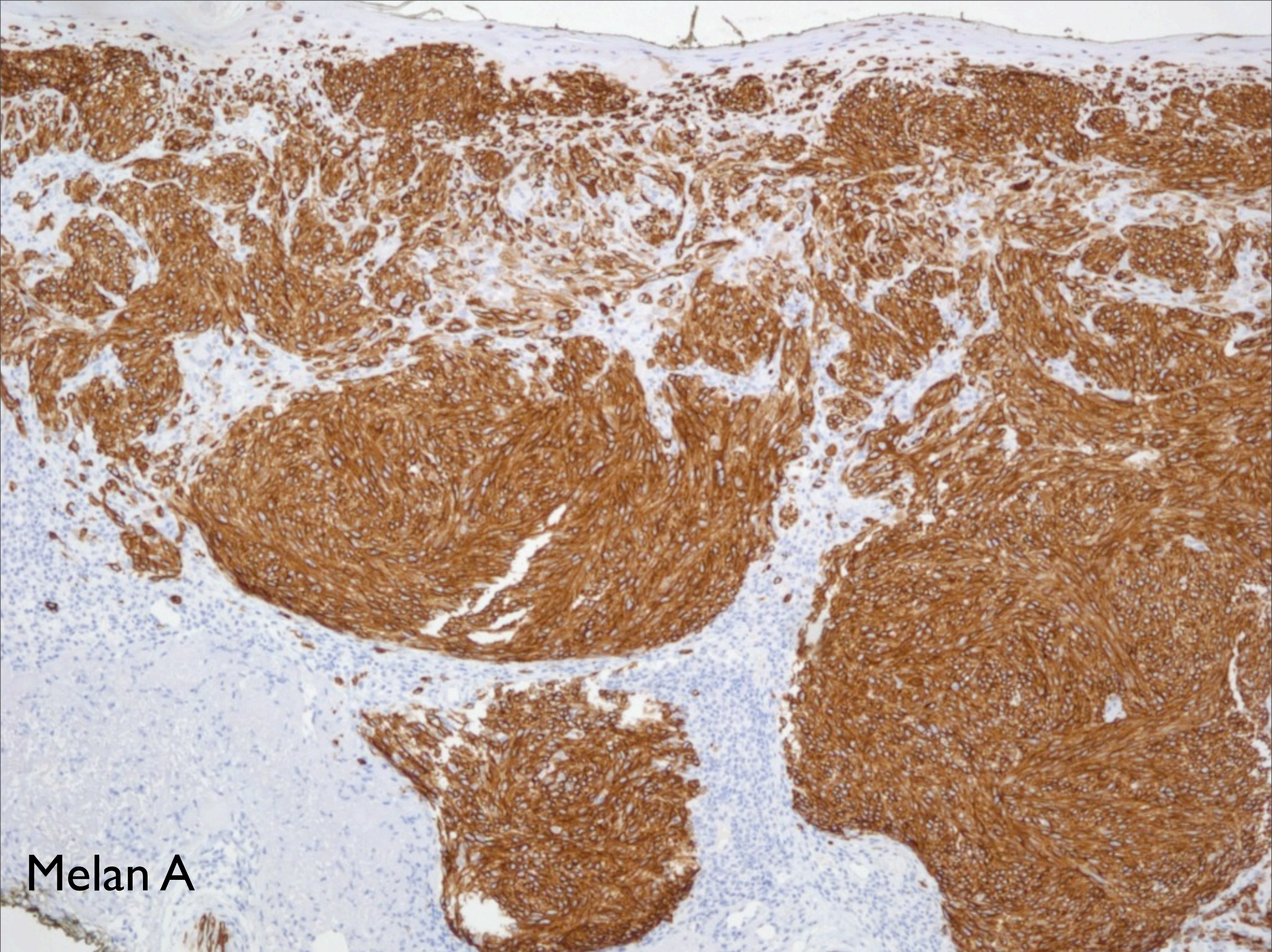






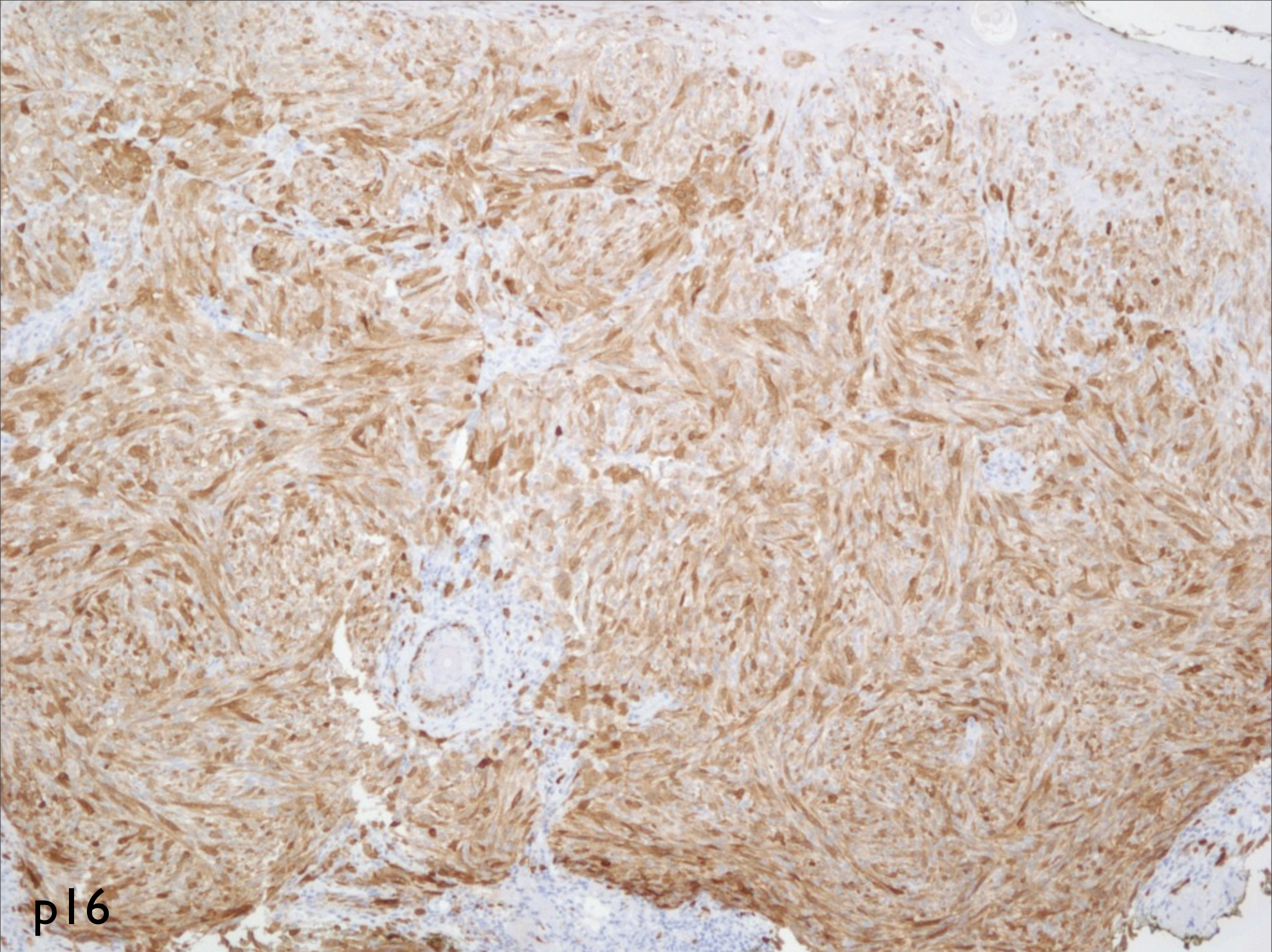






Melan A



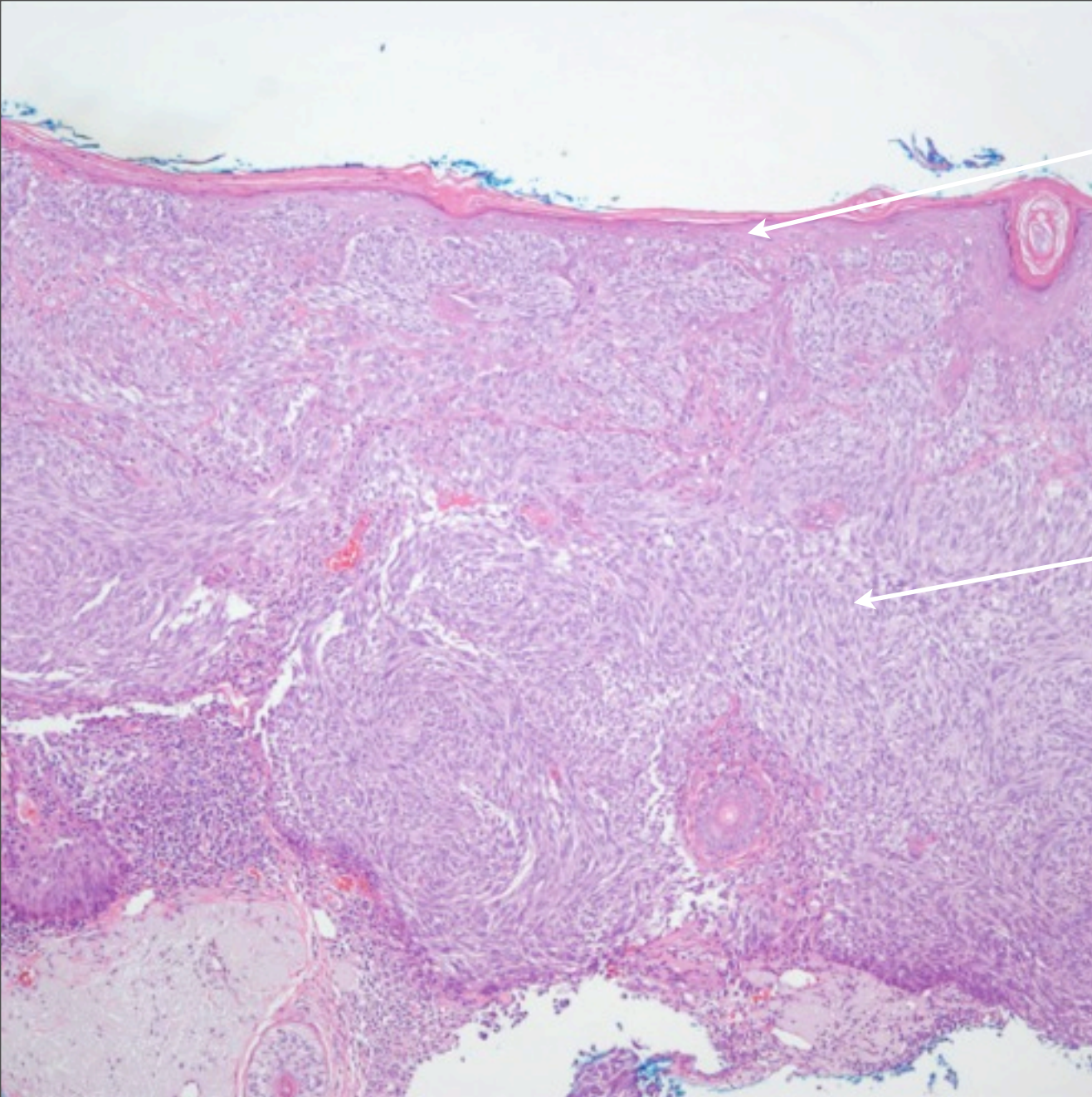


p16



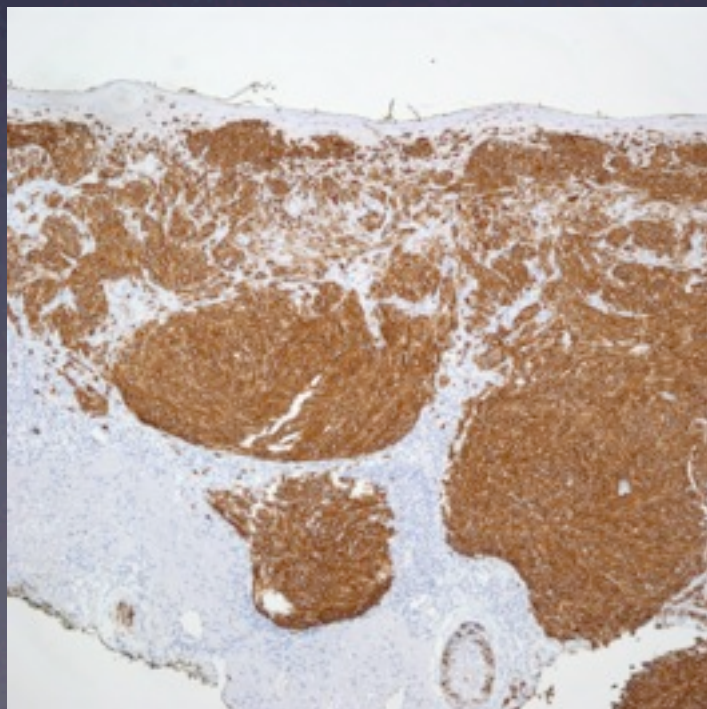
# Malignant Melanoma, Amelanotic Type





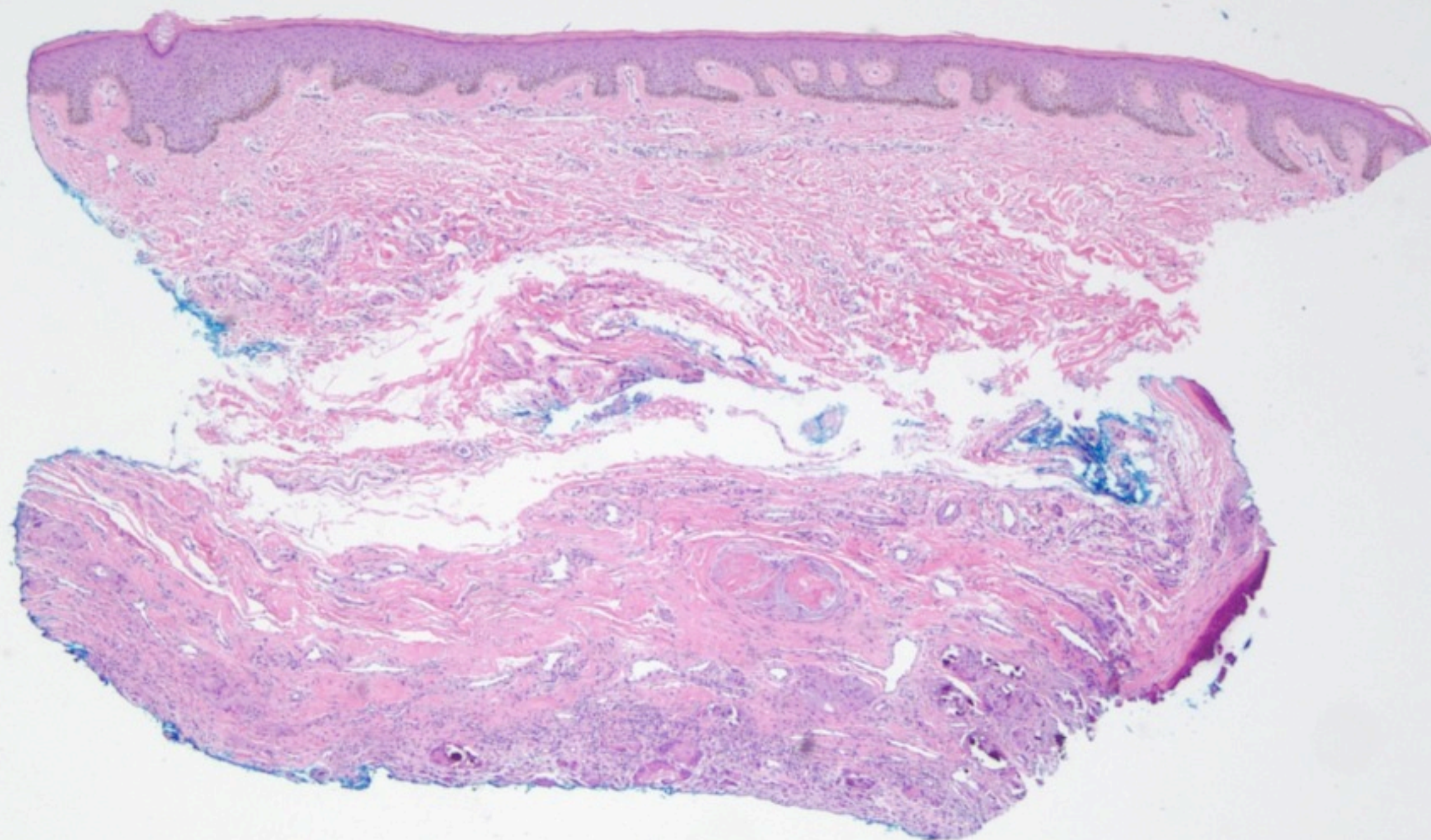
Junctional Nests

Pleomorphic Spindle Cells

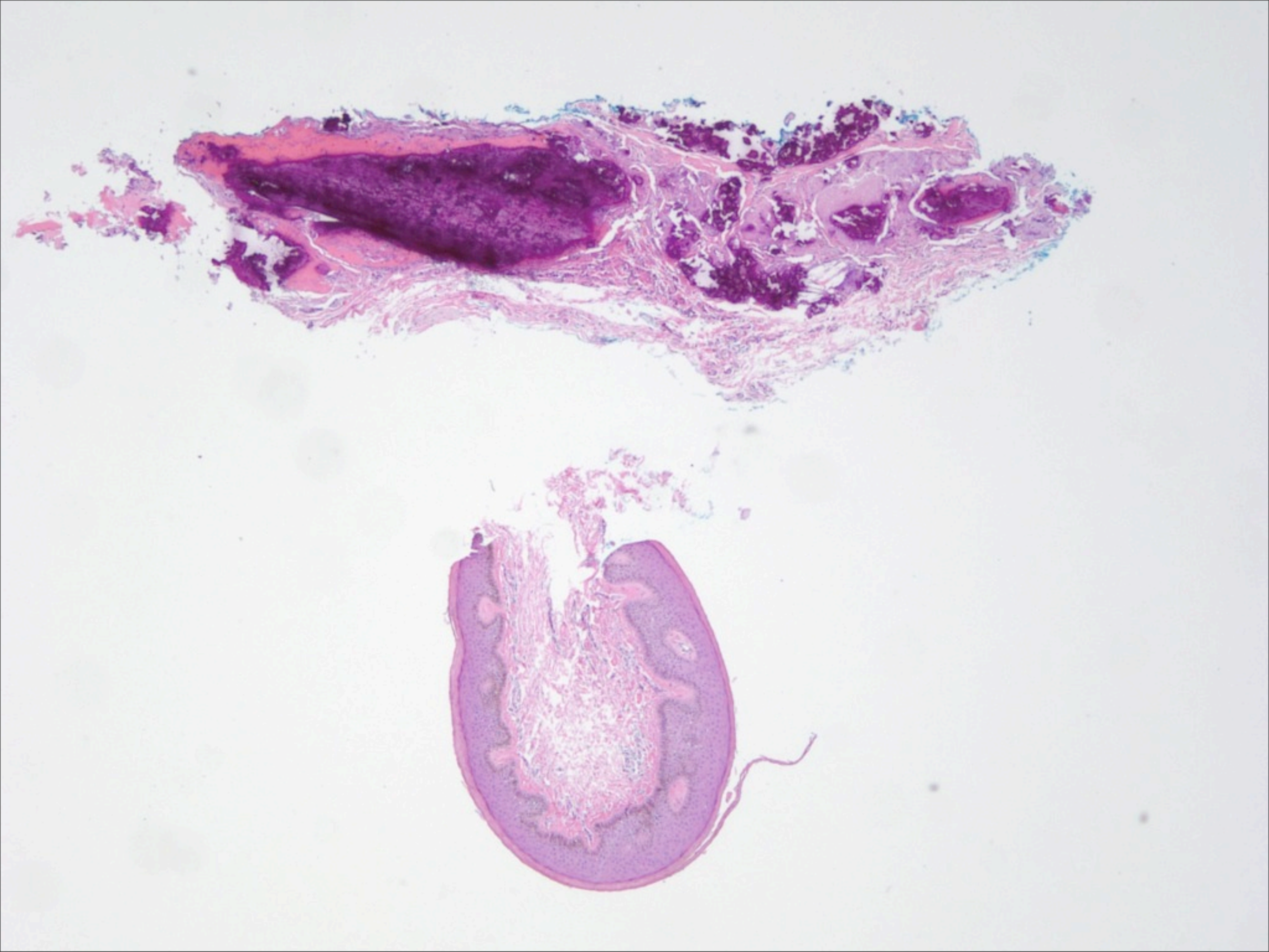


Confirm with  
Immunohistochemistry

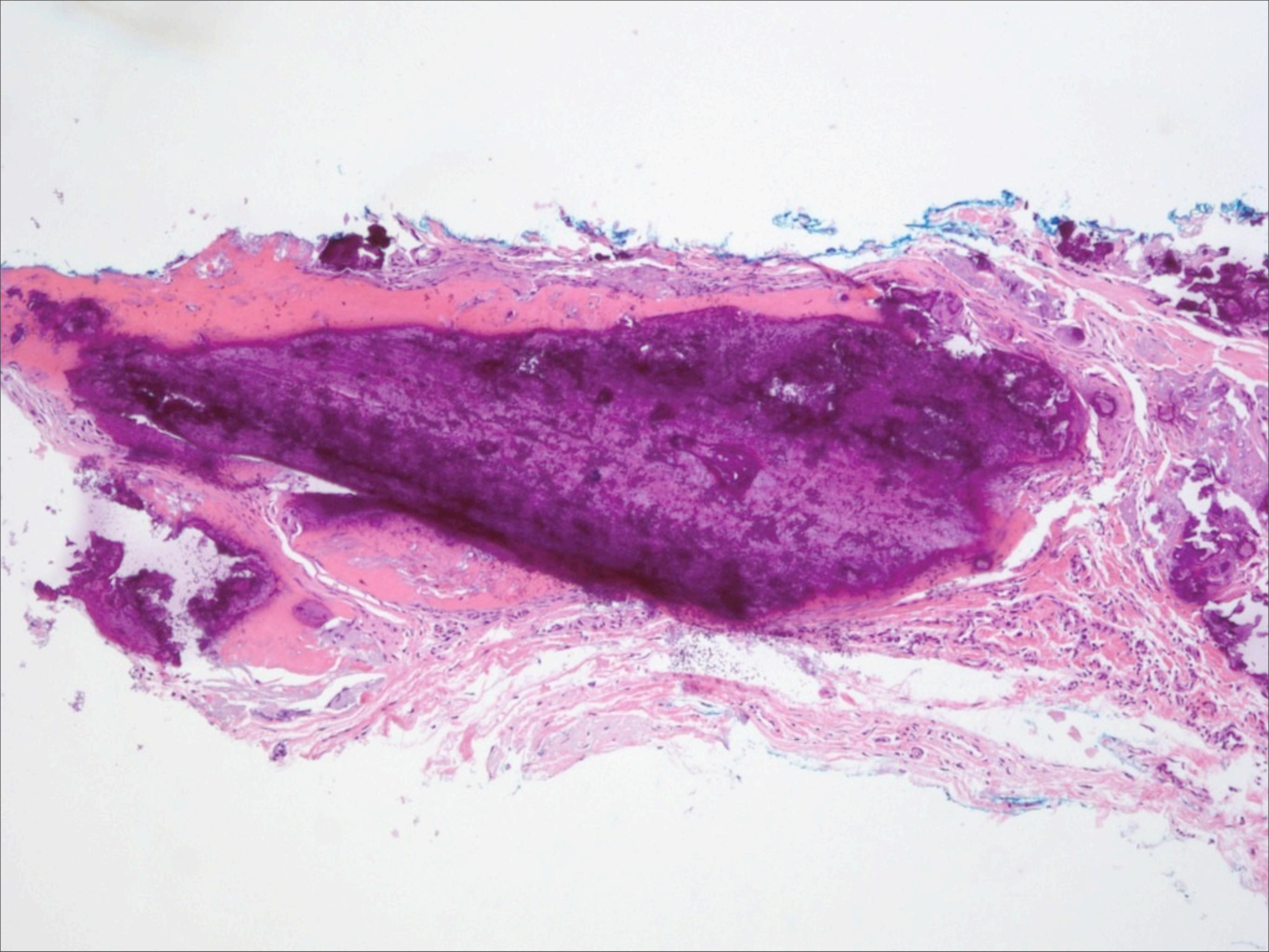




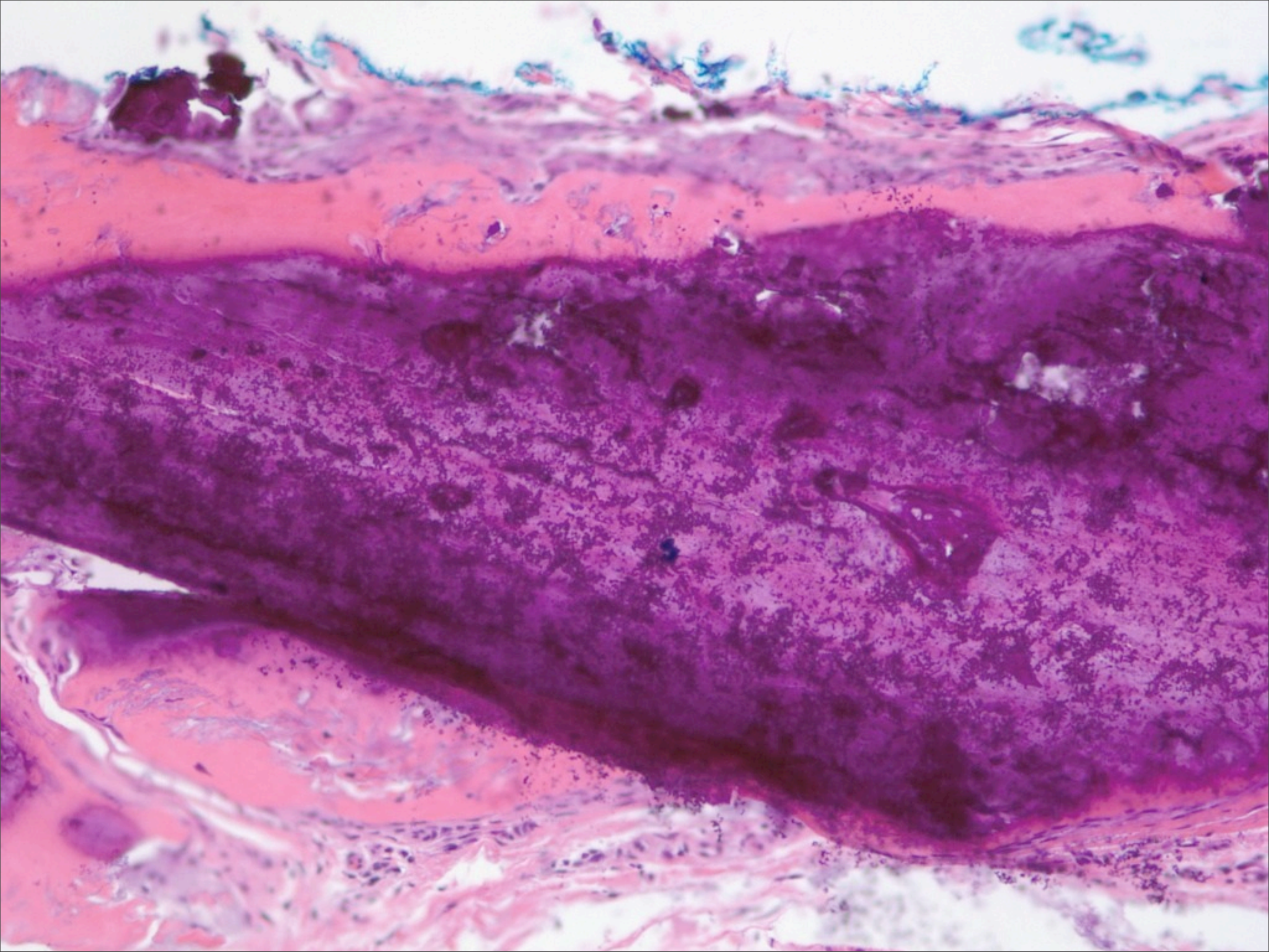










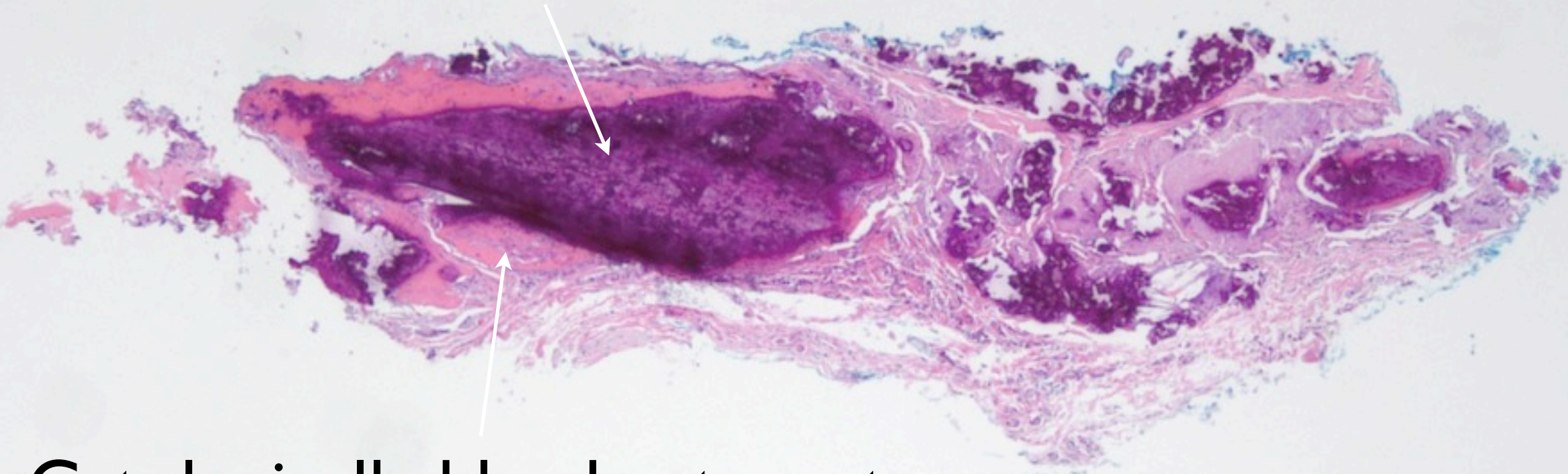




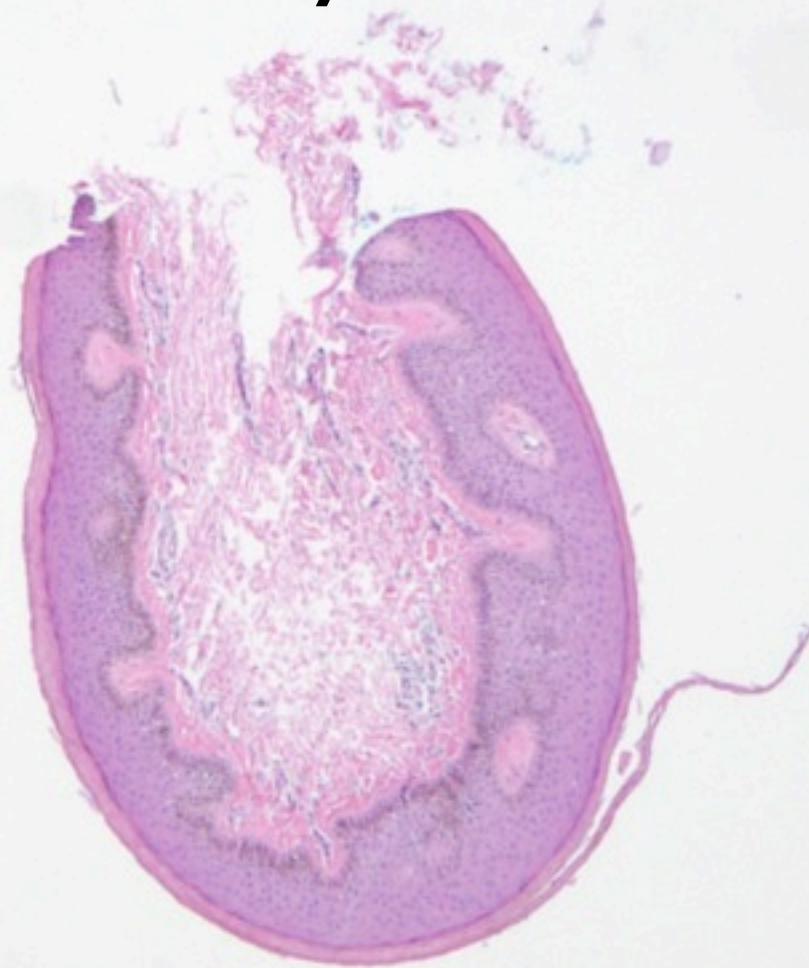
# Osteoma Cutis



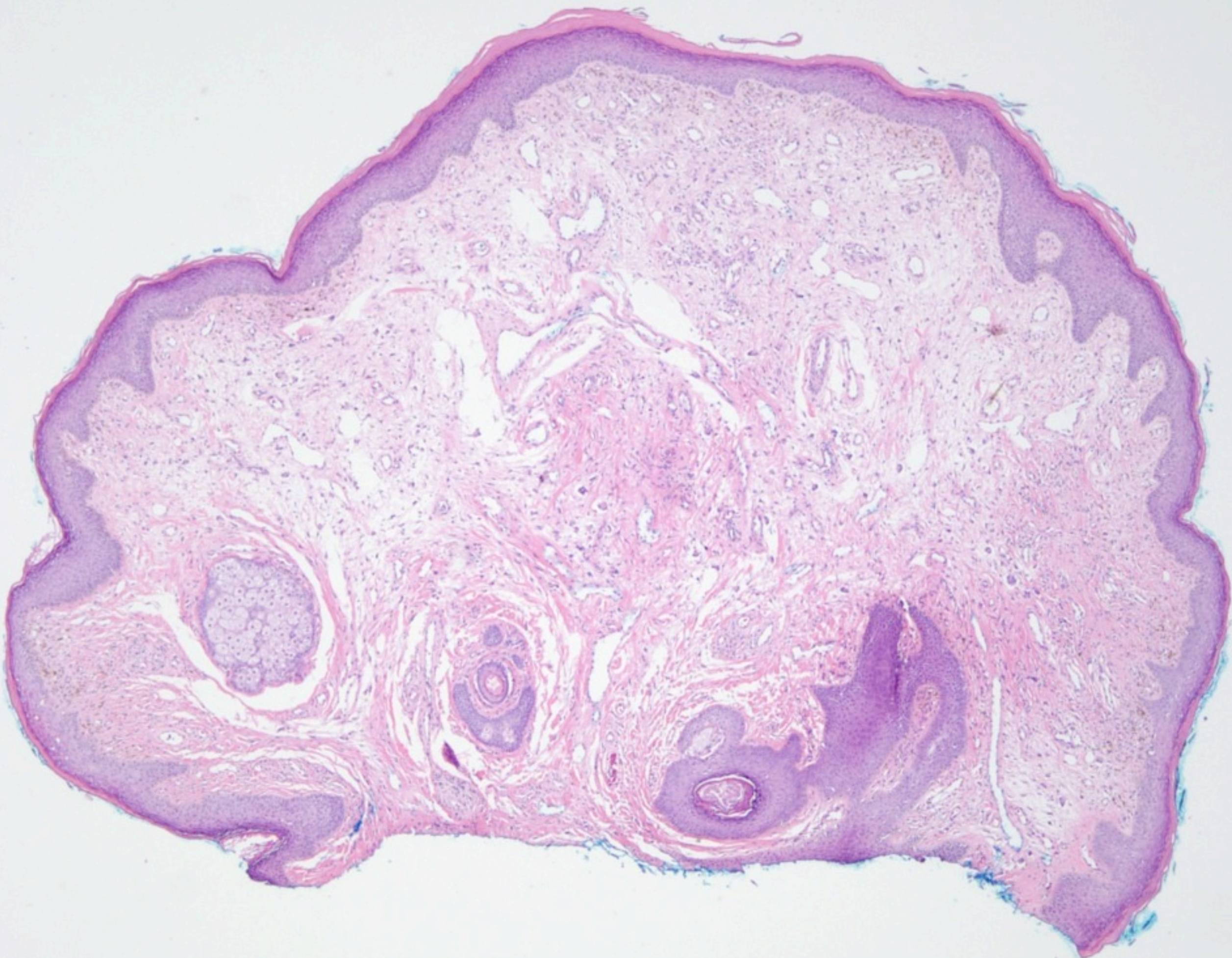
**Mature bone with calcifications**



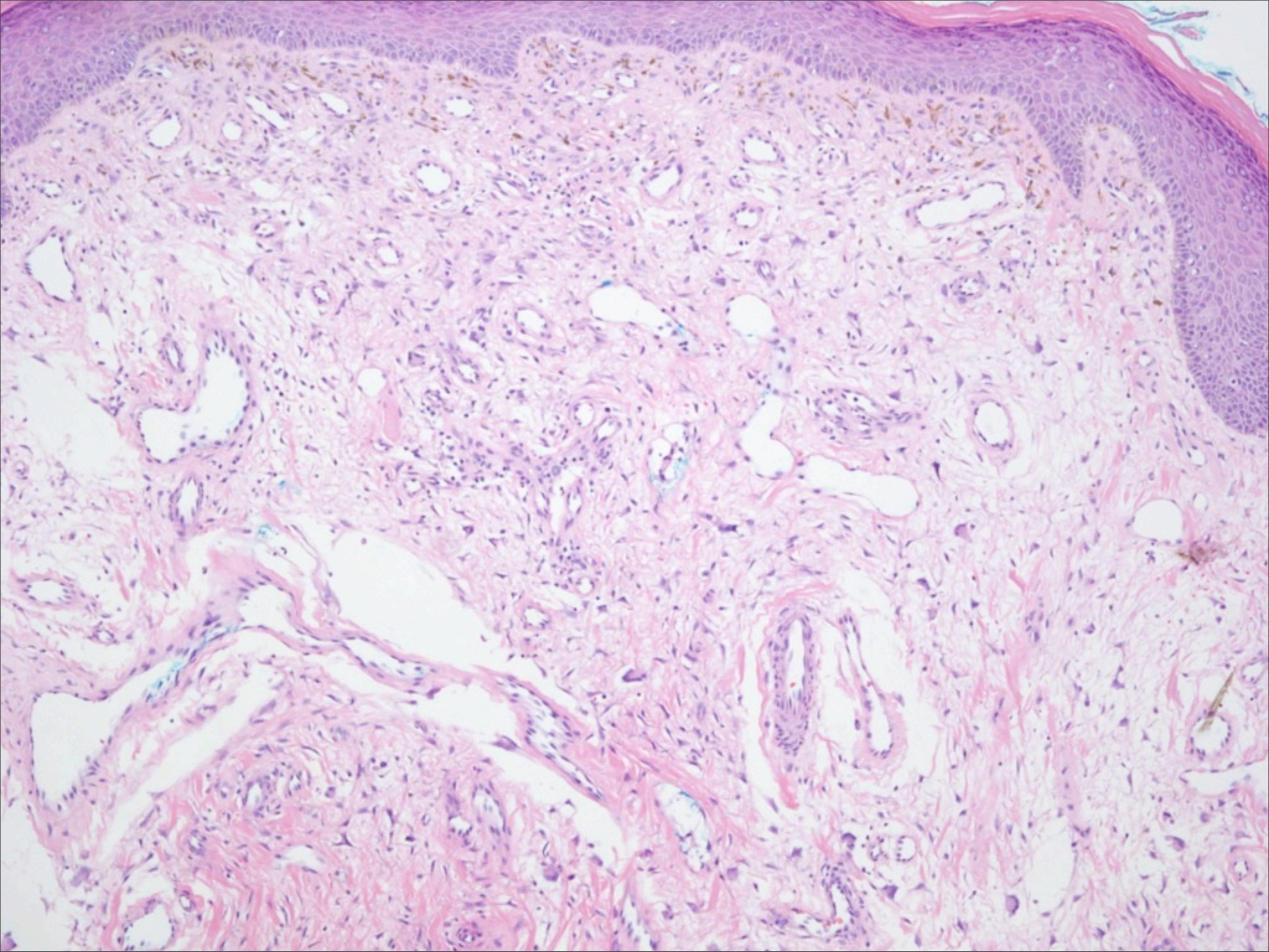
**Cytologically bland osteocytes**



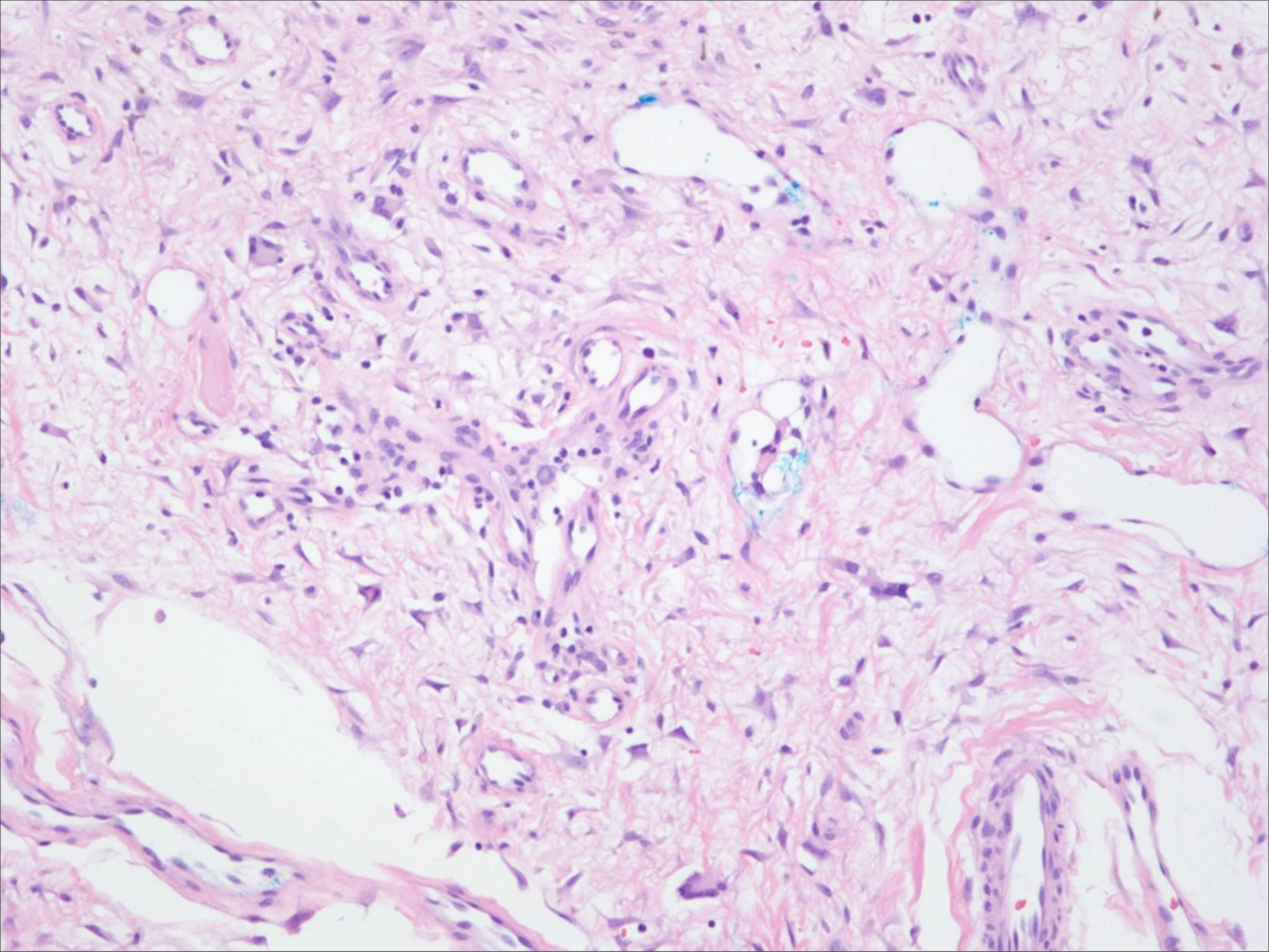




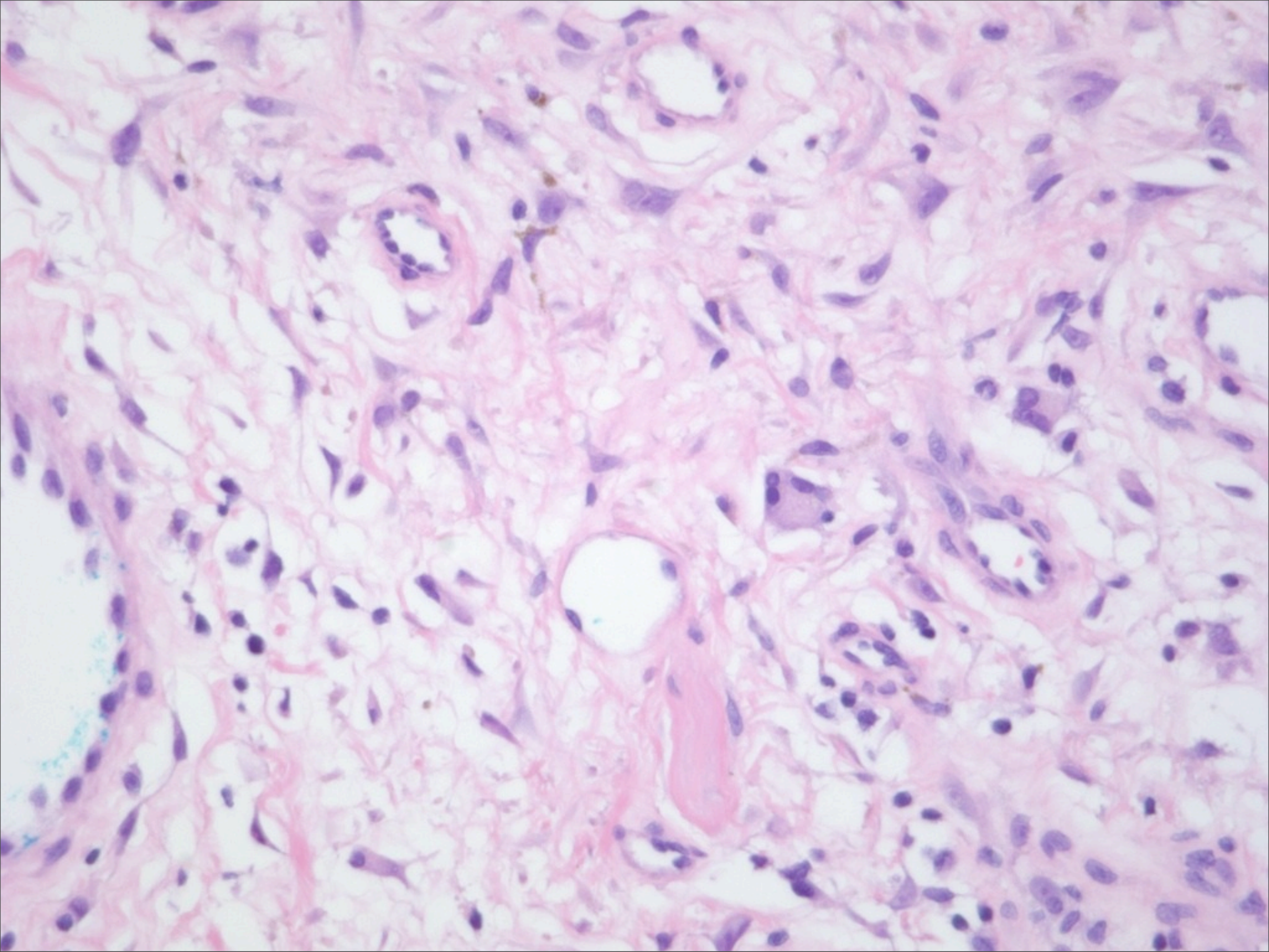














# What is the best diagnosis?

- Angiosarcoma
- Targetoid Hemosiderotic Hemangioma
- Angiolymphoid Hyperplasia with Eosinophilia
- Dabska's Tumor
- Fibrous Papule

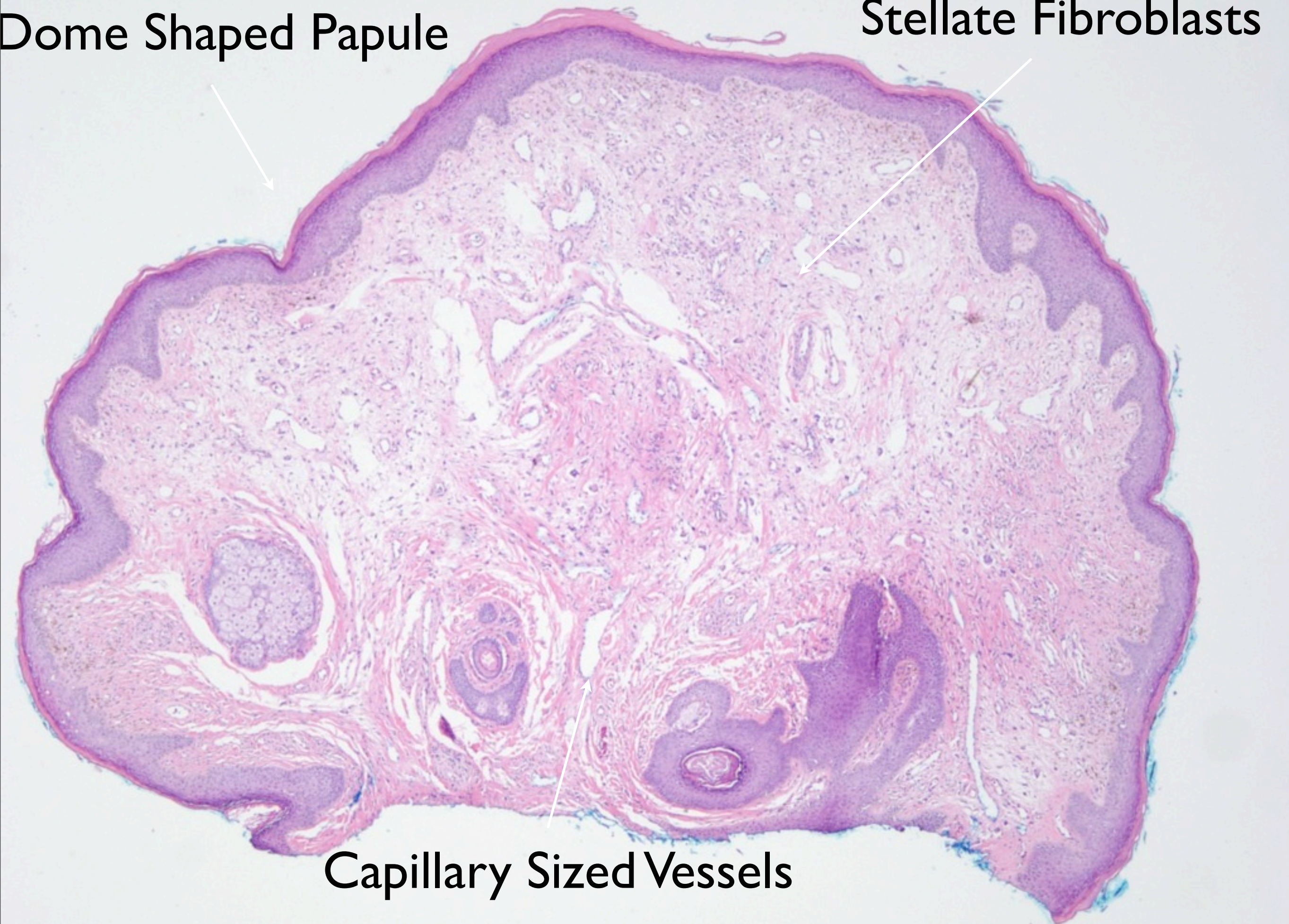


# Fibrous Papule



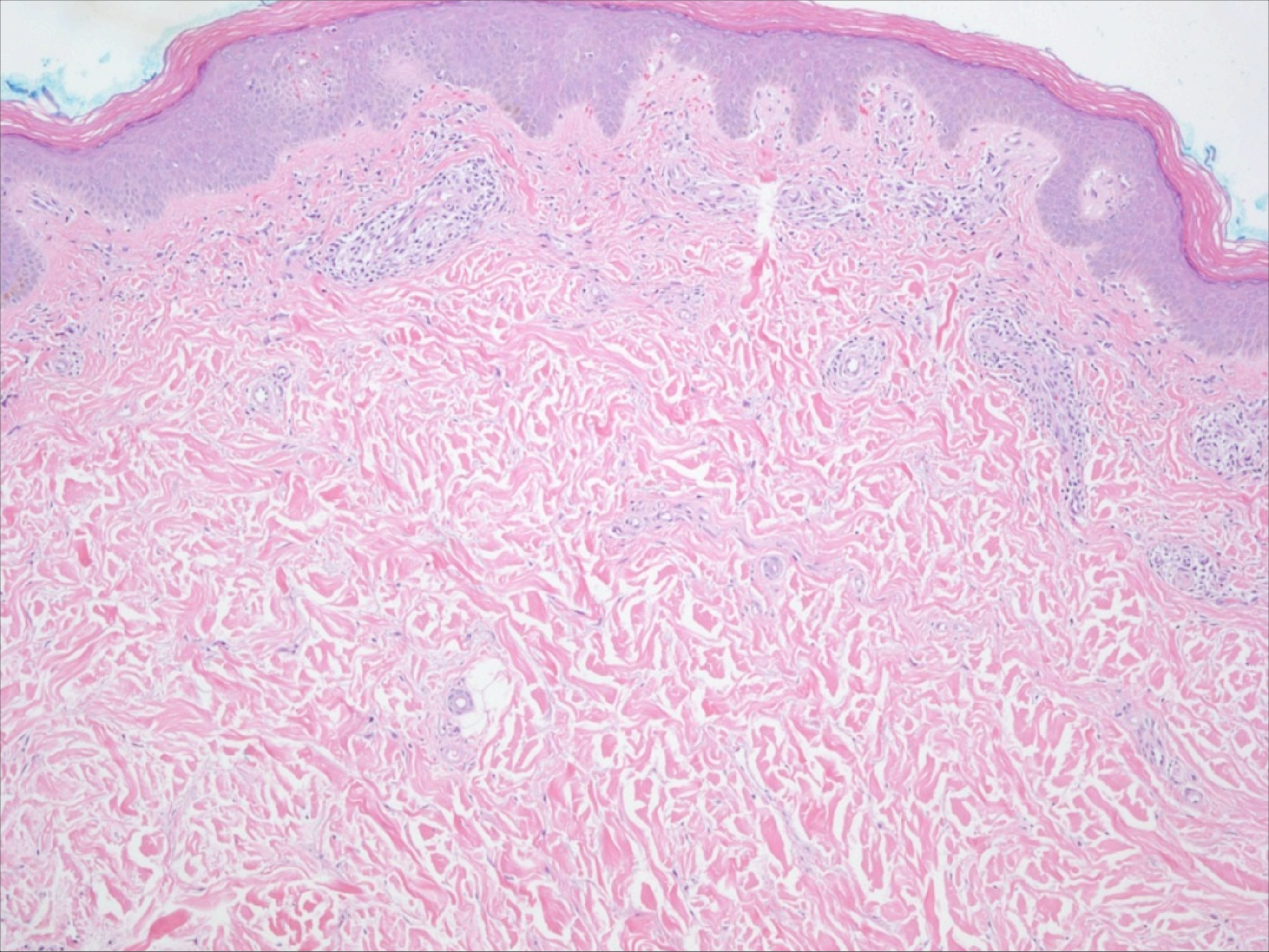
**Dome Shaped Papule**

**Stellate Fibroblasts**

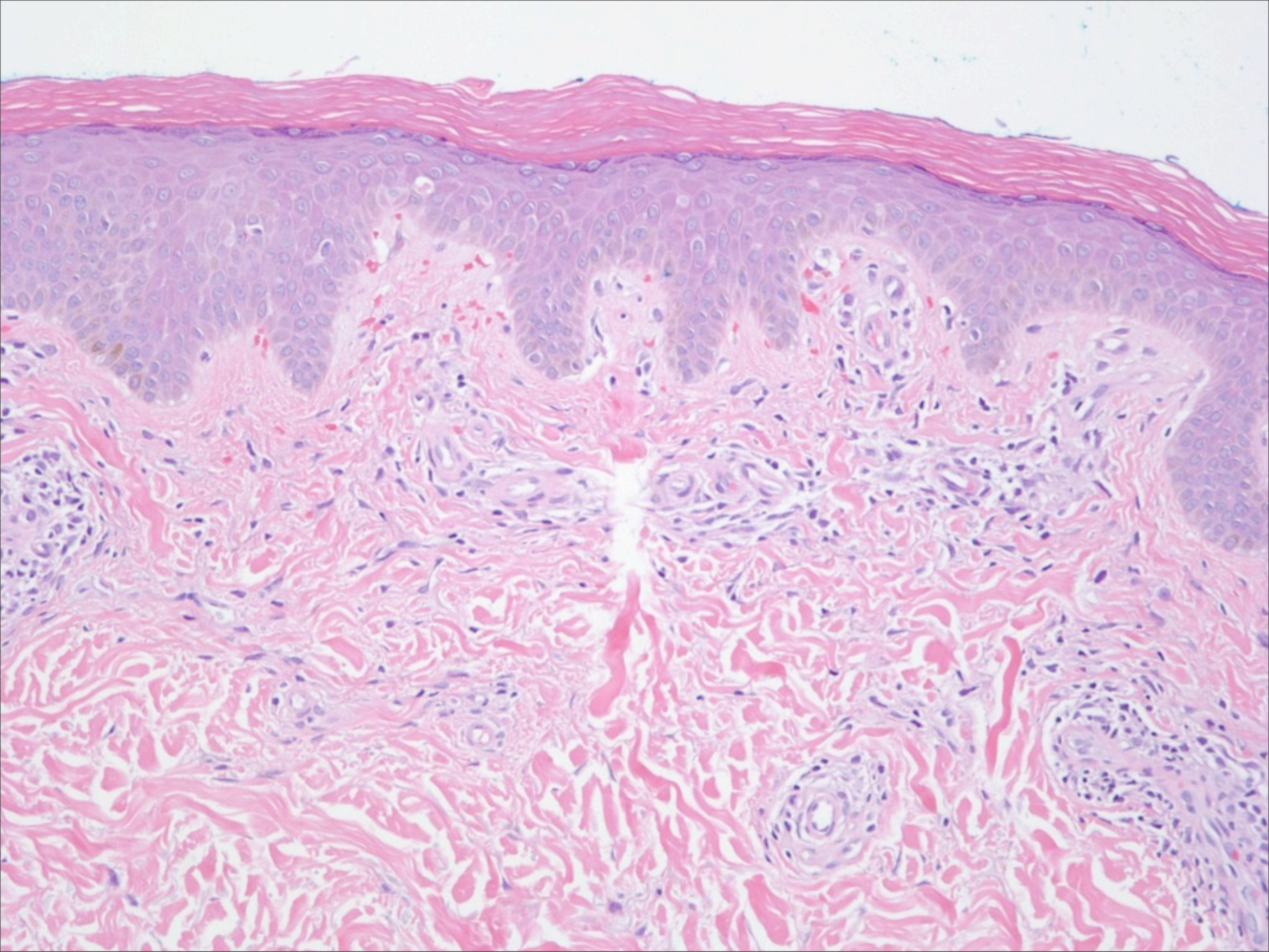


**Capillary Sized Vessels**

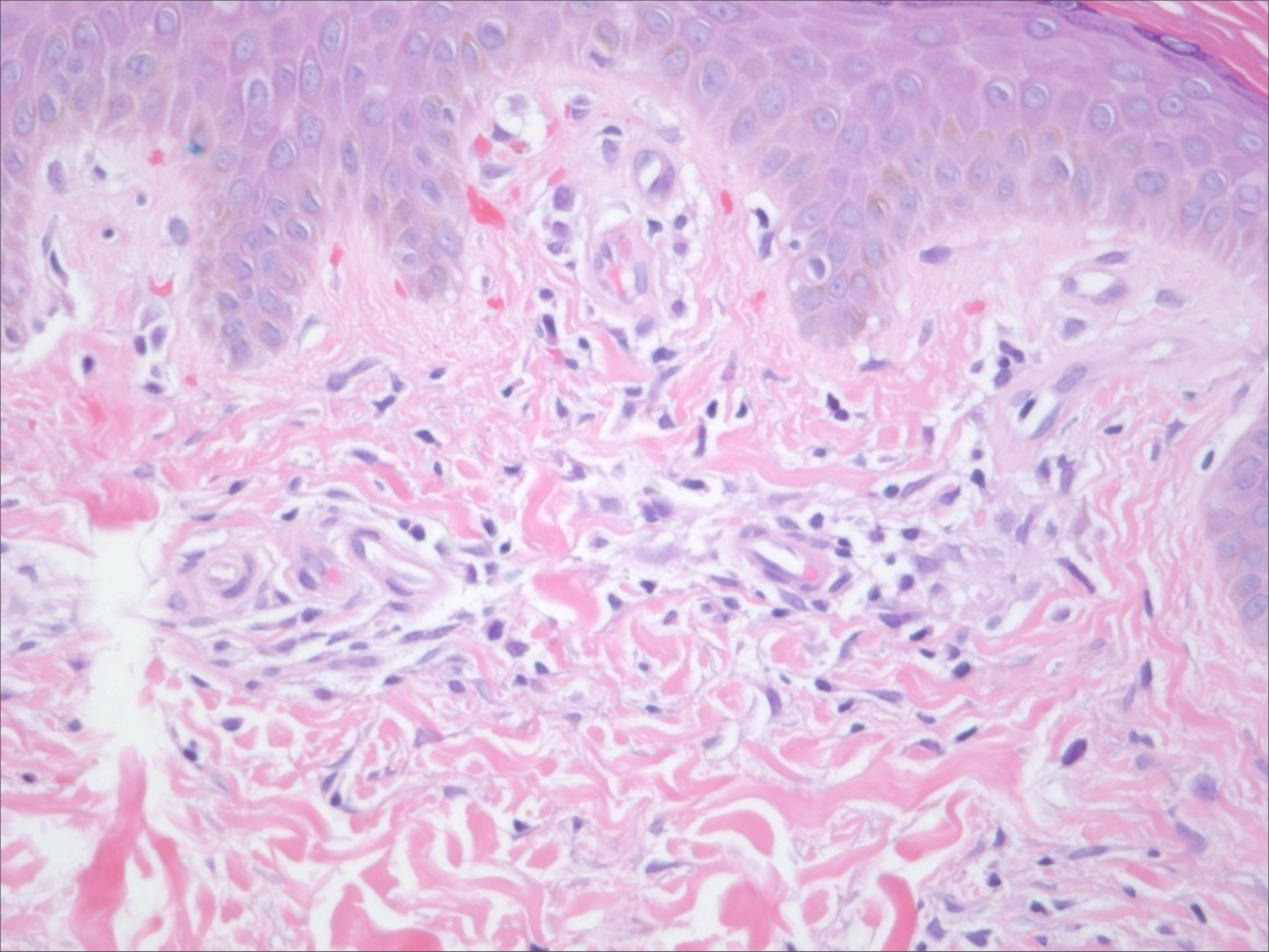














# What is the best diagnosis?

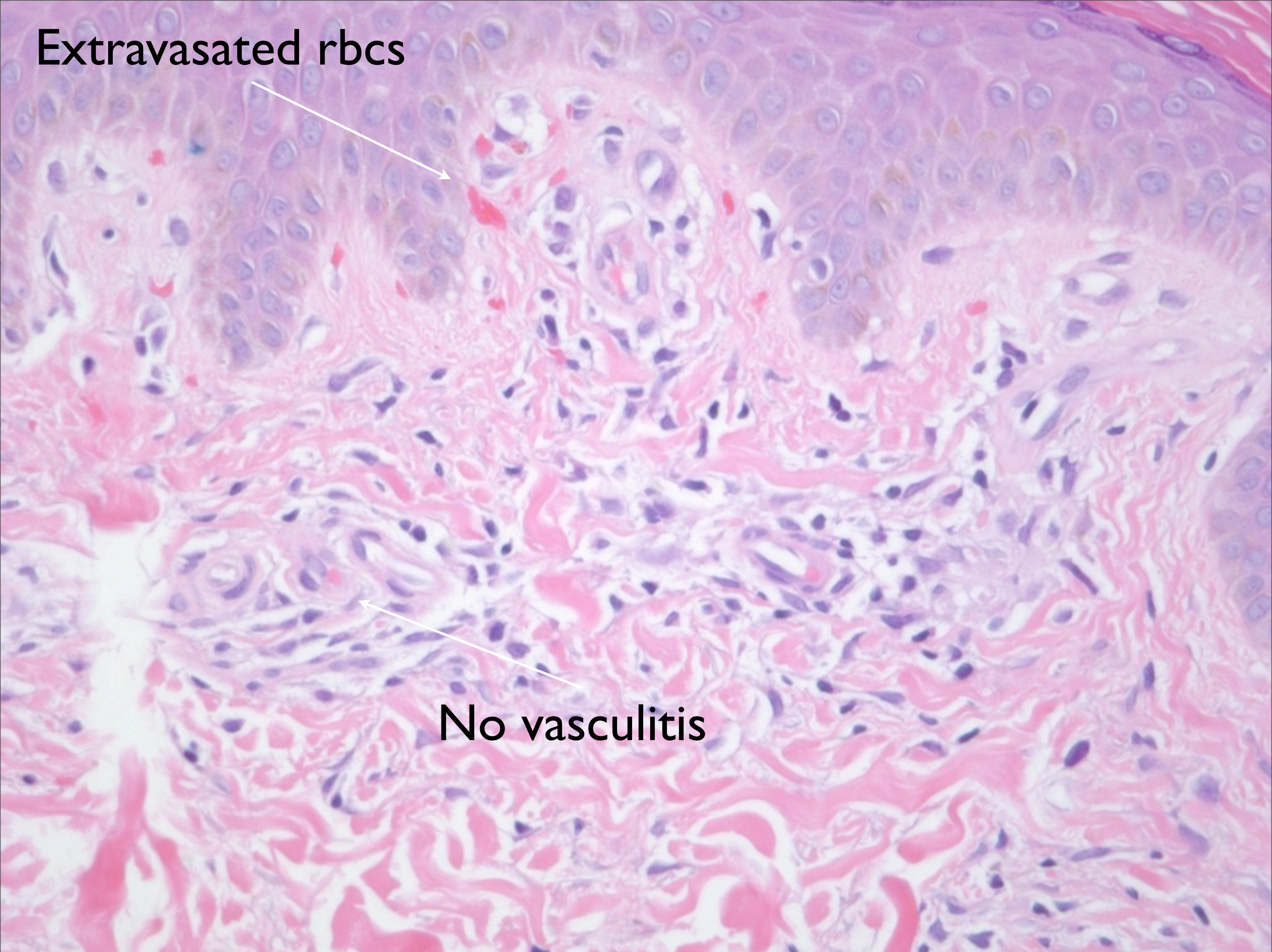
- Leukocytoclastic Vasculitis
- Pigmented Purpuric Dermatoses
- Post-inflammatory pigmentary alterations
- Macular amyloidosis
- Granuloma annulare



# Pigmented Purpuric Dermatosis

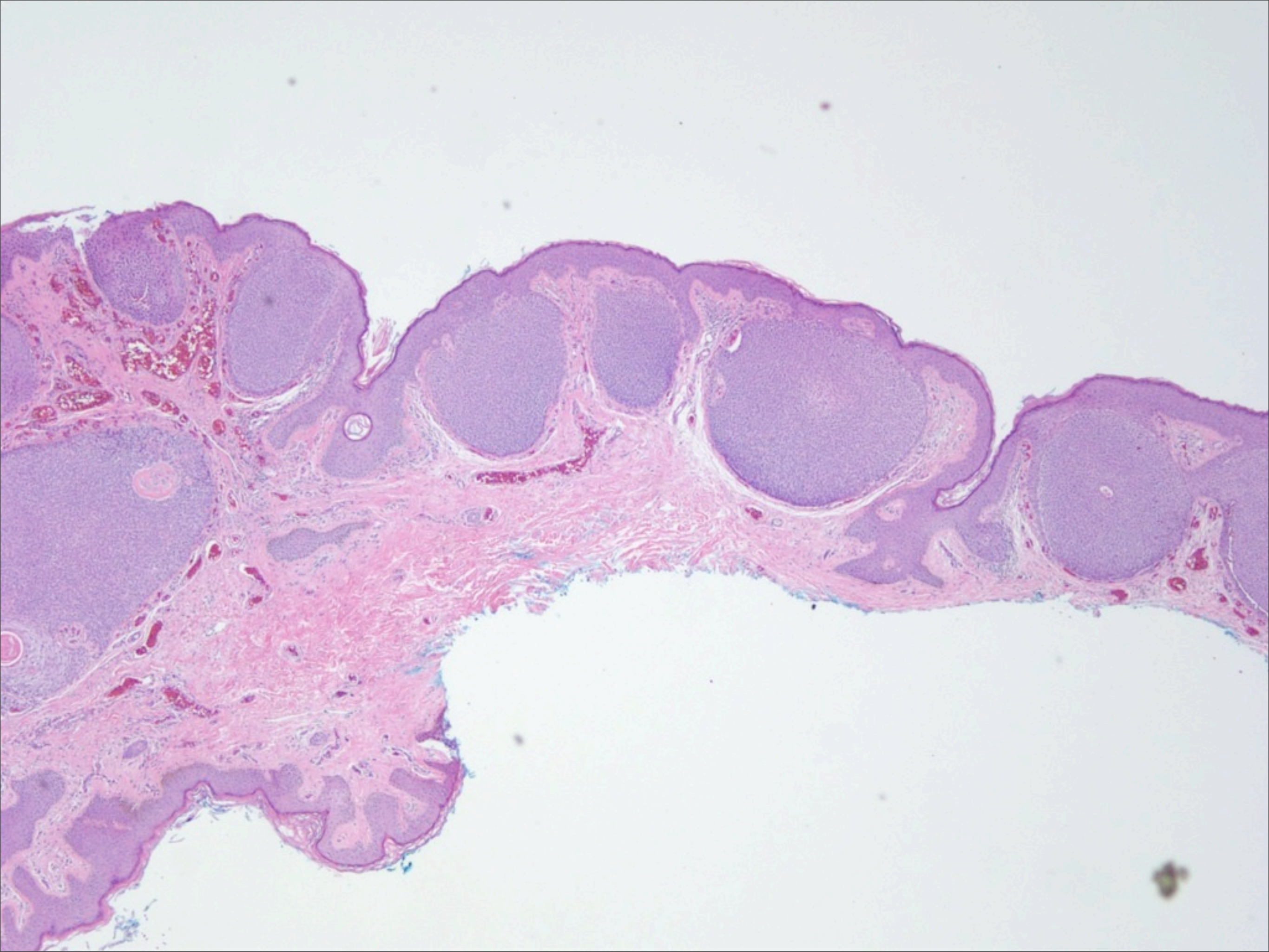


Extravasated rbcs

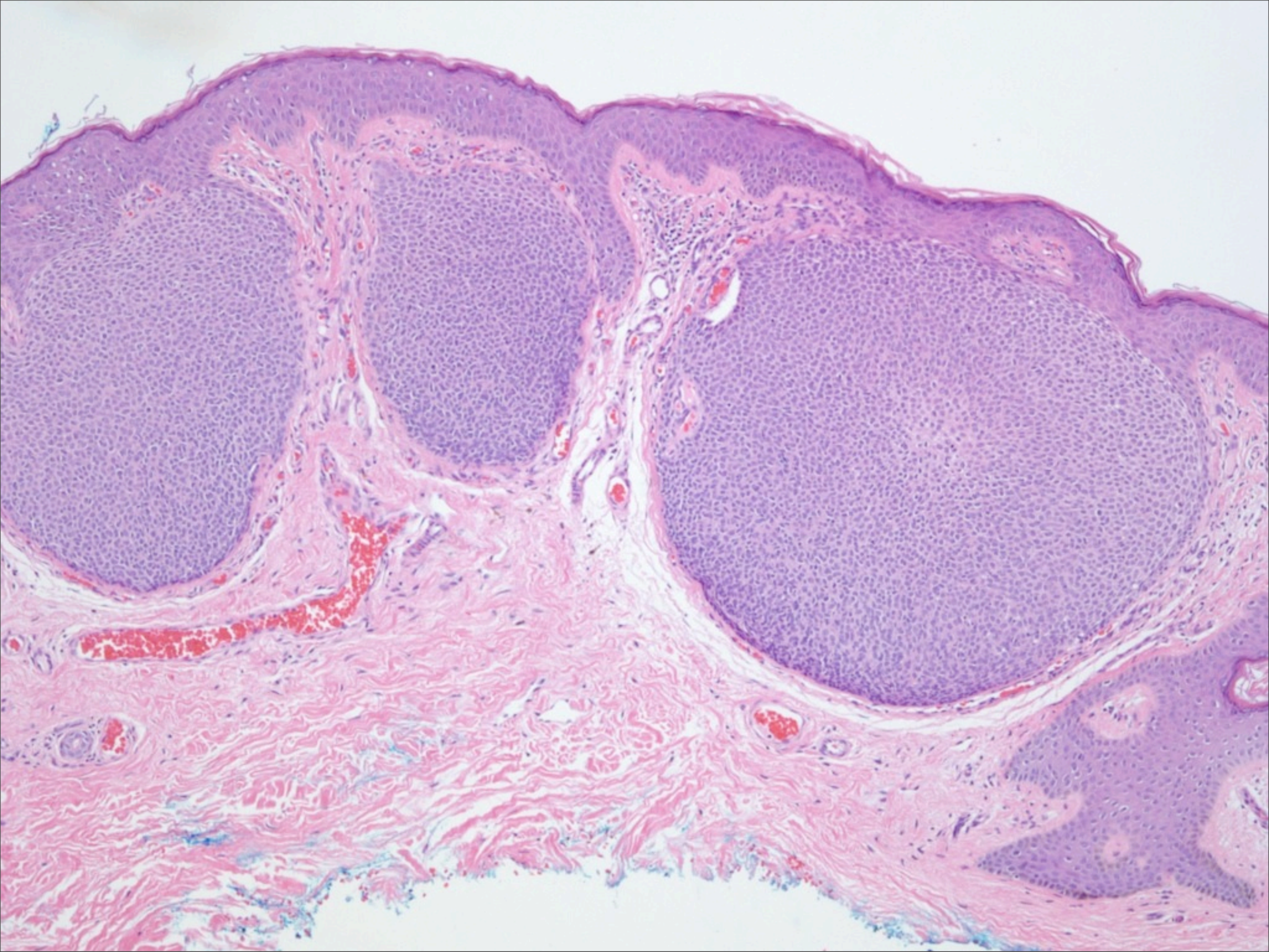


No vasculitis

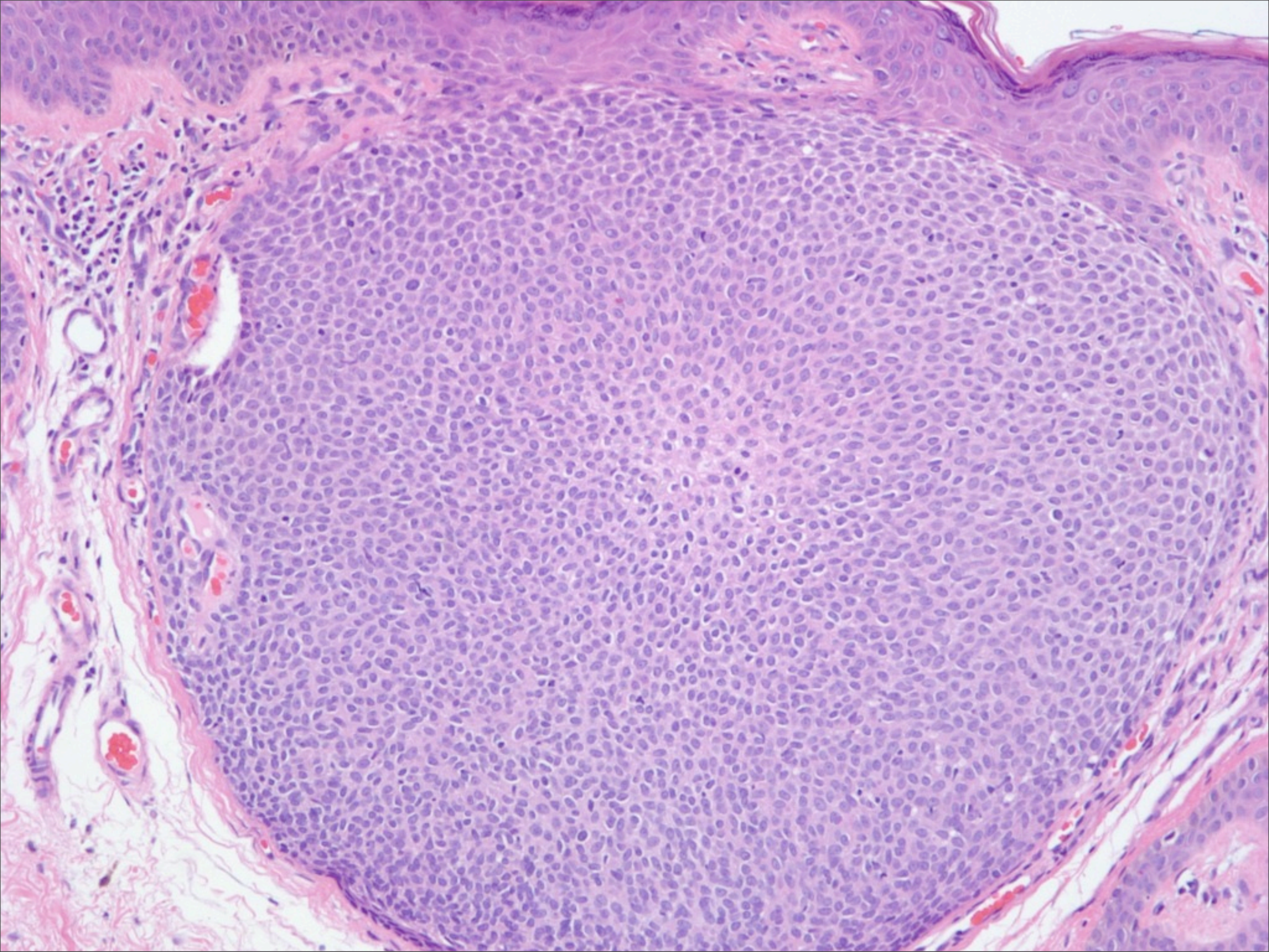




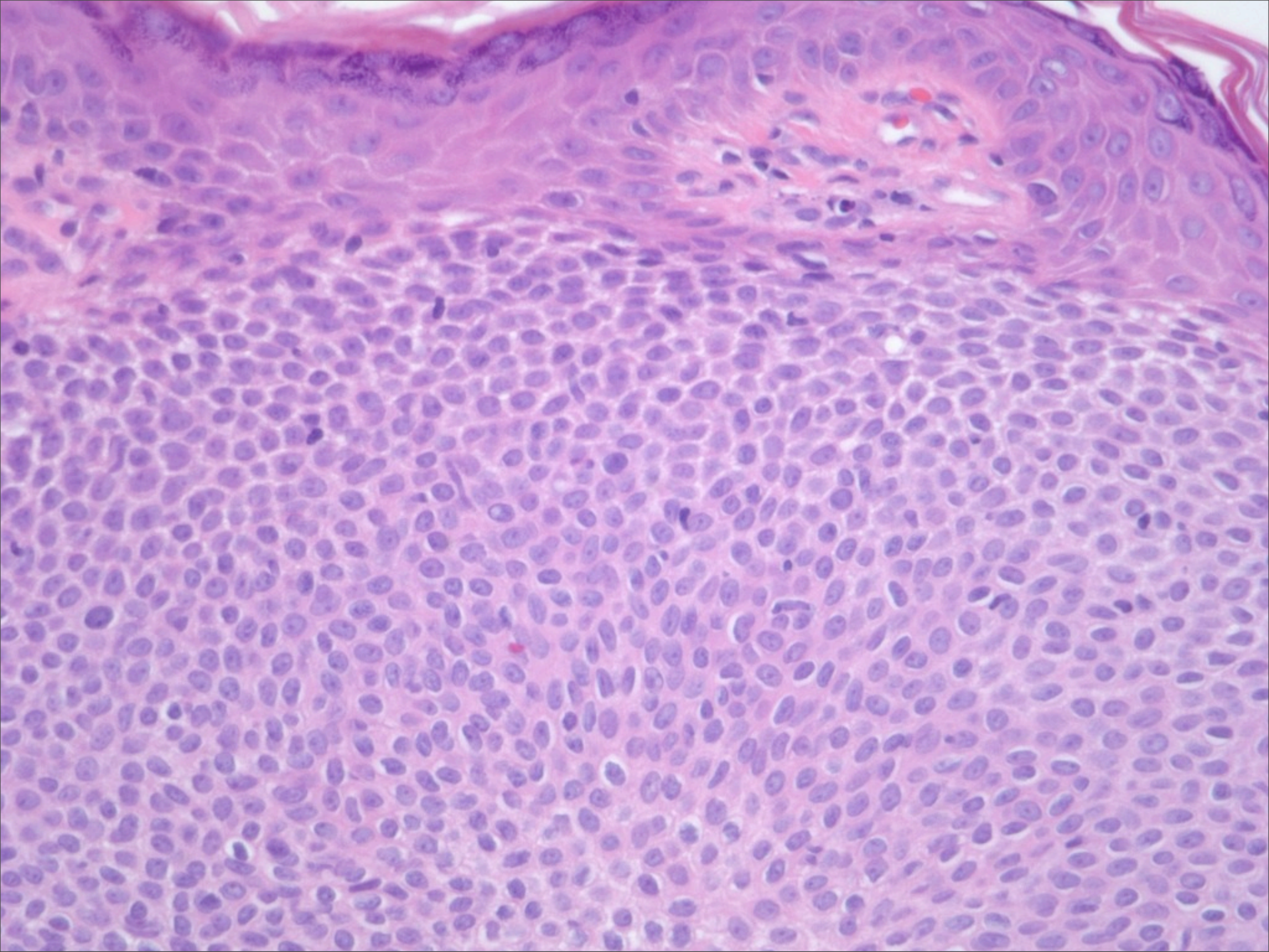














# Hidroacanthoma Simplex

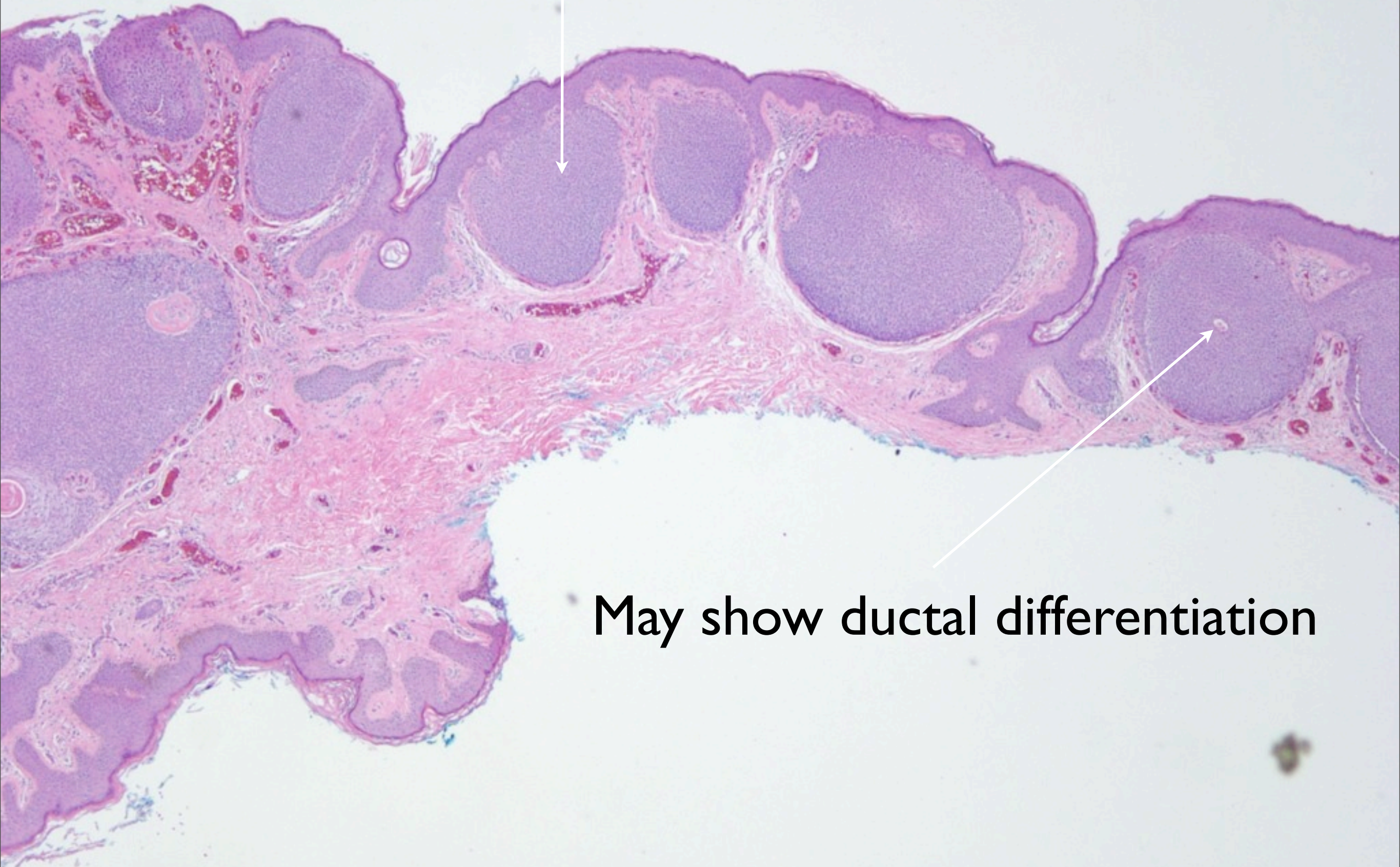


# Notes

- This is essentially an intraepidermal variant of an eccrine poroma
- It illustrates the Borst-Jadassohn phenomenon of a clonal-like intraepidermal expansion
- This may be seen in many conditions including seborrheic keratosis and Bowen's disease



# Circumscribed intraepidermal collection of keratinocytes



May show ductal differentiation